



PROCEEDINGS

FROM THE

FECAVA SYMPOSIUM ON VECTOR-BORNE DISEASES



HW DISEASE AND SUBCUTANEOUS DIROFILARIOSIS OF THE DOG: DIAGNOSIS TO THERAPY

LUIGI VENCO, DMV, SCPA DIPL EVPC, SPECIALIST™ IN PARASITOLOGY
CLINICA VETERINARIA LAGO MAGGIORE DORMELLETO (NO), ITALY, LUIGIVENCO@LIBERO.IT

Despite the name “Heartworm” suggests a primitive cardiac involvement as the main localization of the worms and the first damages are in pulmonary arteries, heartworm disease should be considered a pulmonary disease that in the last stage may involve right cardiac chambers.

Few days after heartworms reach caudal pulmonary arteries, endothelial cells become swollen with wide intercellular junctions and disoriented longitudinal axes, as response to the trauma.

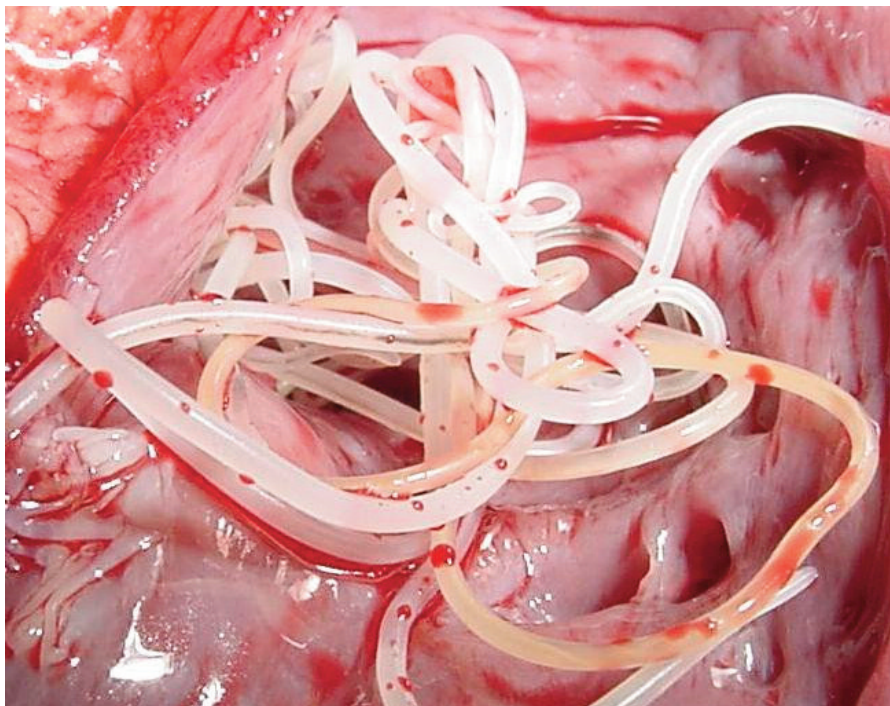Activates neutrophils adhere to the endothelium surface and enter the space between endothelial cells. Furthermore as linear areas of sub endothelium are exposed platelet adhesion and activation is greatly stimulated.

Damaged arterial surface allows albumin, plasma fluid and blood cells to reach the perivascular space.

After the endothelial changes, the intima thickens with fluid, leukocytes invade the wall and smooth muscle cells multiply within tunica media and migrate toward the endo vascular surface as response to growth factor released by platelets. The multiplication and migration of smooth muscle cells cause the presence, on the internal arterial surface, of villi which are made by smooth muscle cells and collagen and covered by endothelial like-cells (Rawlings 1986, Calvert et al. 1988).

The gravity of villous proliferation is directly related to duration of infection and worm burden.

The arterial surface of heavily infected dogs and cats appear rough and velvety, and both the lumen and the compliance of the pulmonary arteries are reduced.



Lung disease occurs secondary to vascular changes. Fluid and protein leaking through the vessel wall of affected arteries produce oedema in the parenchyma. Spontaneous death of some worms can produce thromboembolism and severe inflammatory reactions.

The reduction of compliance and gauge of pulmonary arteries, that can be also occluded by either thromboembolism or severe villous proliferation, results in a hypertensive pulmonary state and, as a consequence, in an increased after load for the right ventricle which can induce “cor pulmonare” and right cardiac congestive heart failure. Protein and fluid leaking through the vessel wall of affected arteries produce furthermore oedema and inflammation in the parenchyma (Dillon et al 1995).

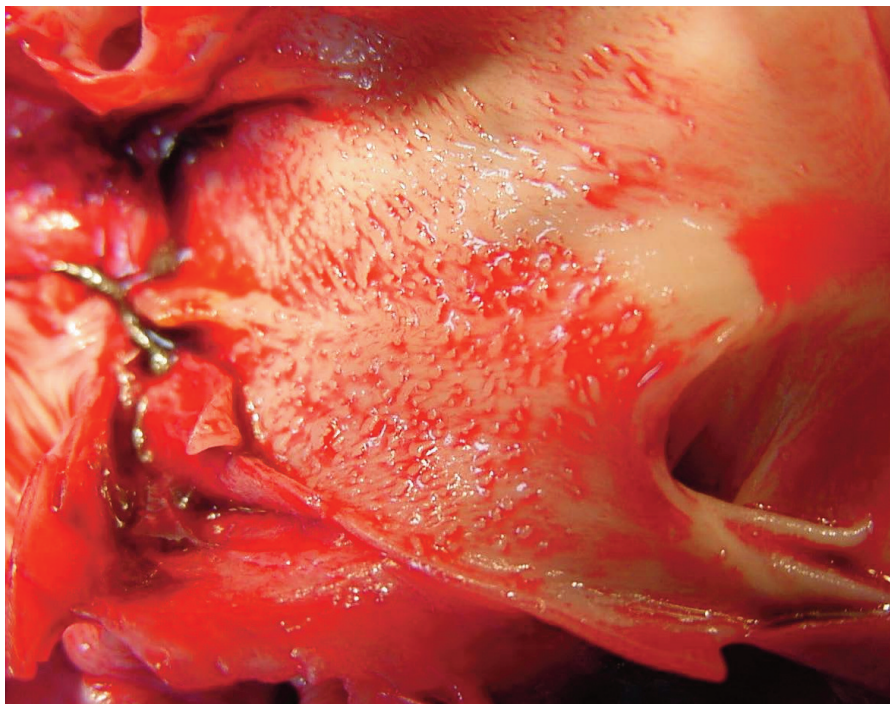
Based on the pathogenesis the clinical evolution of heartworm disease in dogs is usually chronic.

Most infected dogs do not show any symptoms of the disease for a long time, months or years, depending on worm

burden, individual reactivity and exercise, as arterial damages are more severe in dogs with intensive exercise than in dogs at rest (Dillon et al 1995). Signs of the disease develop gradually and may begin with a chronic cough.

Coughing may be followed by dyspnoea, from moderate to severe, weakness, and sometimes lipotimias after exercise or excitement. At this time abnormal pulmonary sounds (crackles) over the caudal lung lobes and second heart sound splitting can be often heard.

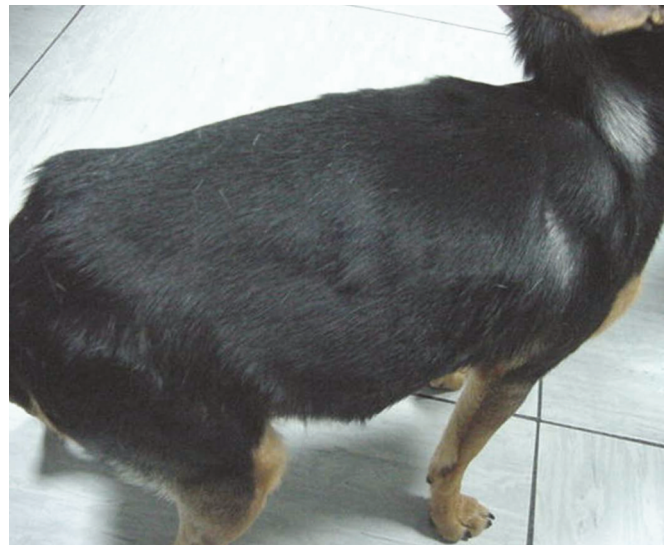Later, when right cardiac congestive failure is developing, swelling of the abdomen and sometimes legs from fluid accumulation, anorexia, weight loss, dehydration, are usually noted. At this stage cardiac murmur over the right side of the thorax due to tricuspid valve insufficiency and abnormal cardiac rhythm due to atrial fibrillation are common findings. Sudden death rarely occurs and usually it happens following respiratory distress or cachexia.



In the chronic pathway of the disease sometimes acute symptomatology may occur. After severe spontaneous thromboembolism following the natural death of many heartworms, dogs may show acute life threaten dyspnoea and haemoptysis.

In small sized dogs is furthermore a common event the displacement of adult worms from pulmonary arteries to right cardiac chambers due to pulmonary hypertension and sudden fall in right cardiac output.

In this case dogs affected shows he so called “Caval syndrome”. Dyspnoea, tricuspidal cardiac murmur and emoglobinuria (due to mechanical haemolysis in right cardiac chambers) are the most typical signs and fatal outcome is usual (Kitagawa et al 1987, Atwel et al 1988, Venco 1993).



DIAGNOSIS

Diagnosis of heartworm infection can be made in dogs by blood test detecting circulating microfilariae or adult antigens but further diagnostic procedures are usually required to determine the severity of disease and which is the best treatment (Knight 1995)²⁷.

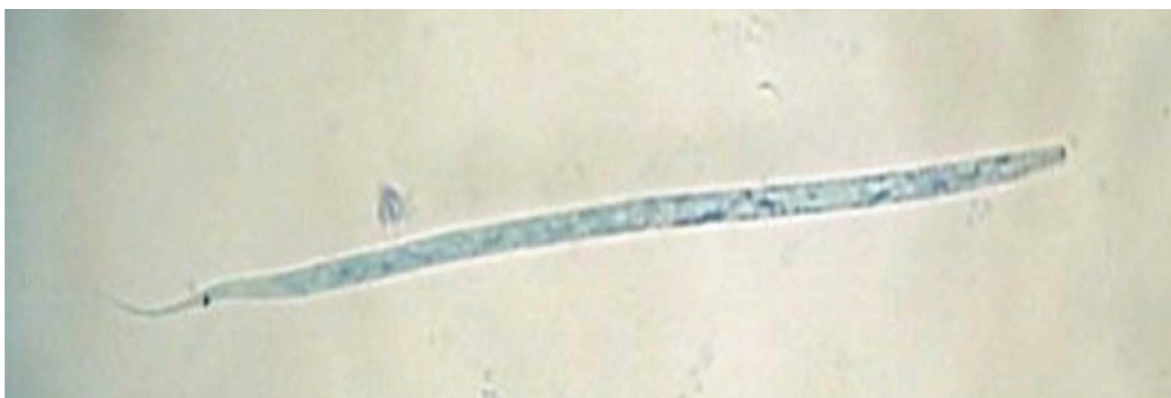BLOOD TEST FOR MICROFILARIAE

Blood sample is examined after concentration (Knott or Difill test) for the presence of microfilariae.

If microfilariae are seen and identified as *D.immitis*, based on morphology that is considered a definitive proof of infection (specificity 100 %)

However up to 30 % of dogs do not have circulating microfilariae even though they harbour adult worms, due to the presence of only worms of the same sex, immune reactivity of the host to microfilariae or administration of microfilaricidal drugs.

The sensitivity of test for microfilariae is not therefore considered sufficient to rule out the infection in case of negative test.



BLOOD TEST FOR ADULT ANTIGENS

Test designed to detect heartworms adult antigens based on ELISA or colloidal gold staining techniques are considered highly specific as cross reactivity with other dogs parasites (i.e. *D.repens*, *Dipetalonema* sp.) does not occur.

These tests allow detection of adult heartworm antigens produced only by female worms and may provide information about worm burden (Knight 1995, Venco et al 2004).

The sensitivity is actually very high, but false negative results may occur in prepatent or very light infections or when only male worms are present (Mc Call 1992).

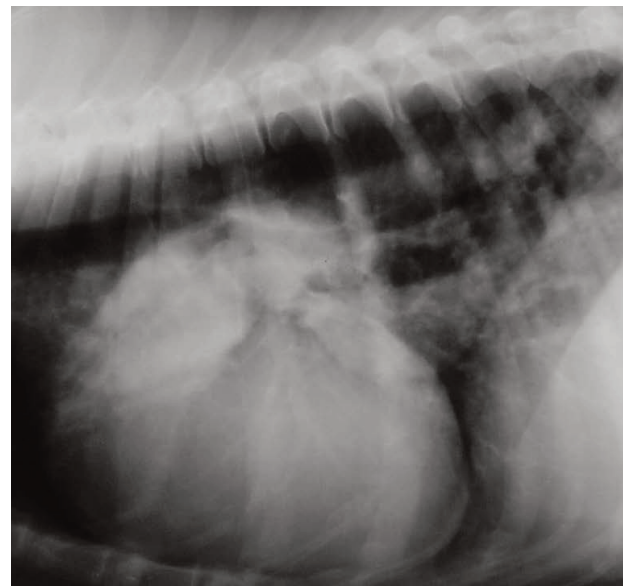


THORACIC RADIOGRAPHS

Thoracic radiographs may show, in the advanced stage, enlargement of the pulmonary arteries, abnormal pulmonary patterns and in the worst cases right sided cardiomegaly. If congestive right heart failure is present peritoneal and pleural effusion can be noted (Rawlings 1986, Calvert et al. 1988). They are useful to assess the severity of the pulmonary lesions but not for evaluating worm burden (Venco et al 2004).

Since radiographic signs of advanced pulmonary vascular disease may persist long after an infection has run its course, some of the most severely diseased dogs may have disproportionately low worm burden.

On the contrary some inactive dogs may have large worm burdens and be clinically asymptomatic with no or trivial radiographic lesions.



ELECTROCARDIOGRAPHY

As electrocardiogram displays the electrical activity of the heart, abnormalities, (electrical axis right deviation, atrial fibrillation) are usually found only in the last stage of the disease, when right cardiac chambers present severe damages.

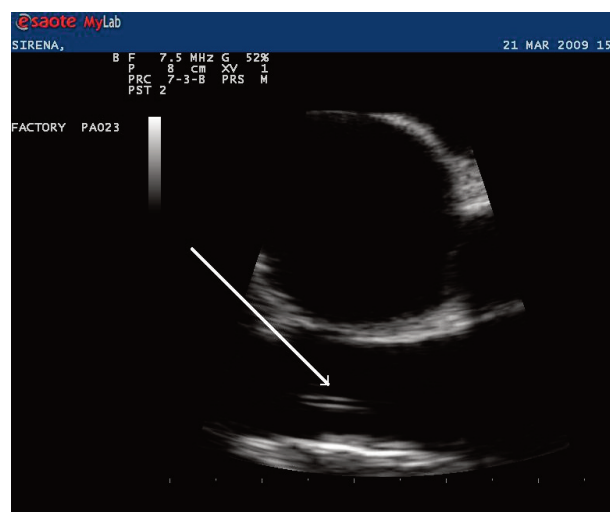
ECHOCARDIOGRAPHY

Echocardiography allows a direct visualization of cardiac chambers and connected vessels (Moise 1988).

It also allows the visualization of parasites in right cardiac chambers, caudal vena cava, main pulmonary artery and proximal tract of both caudal pulmonary arteries. The heartworms are visualized as double, linear parallel objects floating in the right cardiac chambers or into the lumen of vessels (Moise 1988, Badertscher et al 1988).

It is performed mainly in cases where clinical and radiographic findings suggest severe disease.

Cardiac ultrasound can increase the accuracy in staging the disease and estimating the worm burden, both of which affect the treatment program and the prognosis.

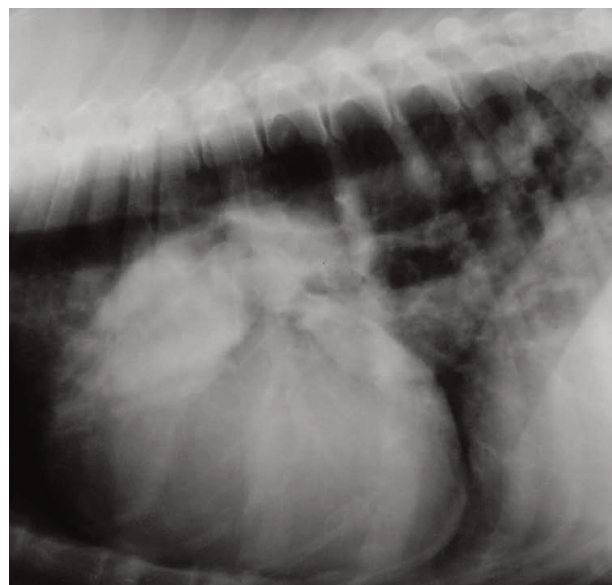


THORACIC RADIOGRAPHS

Thoracic radiographs may show, in the advanced stage, enlargement of the pulmonary arteries, abnormal pulmonary patterns and in the worst cases right sided cardiomegaly. If congestive right heart failure is present peritoneal and pleural effusion can be noted (Rawlings 1986, Calvert et al. 1988). They are useful to assess the severity of the pulmonary lesions but not for evaluating worm burden (Venco et al 2004).

Since radiographic signs of advanced pulmonary vascular disease may persist long after an infection has run its course, some of the most severely diseased dogs may have disproportionately low worm burden.

On the contrary some inactive dogs may have large worm burdens and be clinically asymptomatic with no or trivial radiographic lesions.



THERAPY

It has been said that the treatment of heartworm infection is difficult. There are several strategies that can be used including the option of not treating at all. The important concept to realize is that treating for heartworm infection is neither simple nor safe in itself.

Prior to therapy, the heartworm patient is assessed and rated for risk into one two categories. Important factors include: how

many worms are thought to be present based upon the ELISA tests performed and ultrasound examination (Venco et al 2004), the size of the dog, the age of the dog, harbouring medium age dogs (Venco et al 2004) the largest worm burden, concurrent health factors, severity of the pulmonary disease, and the degree to which exercise can be restricted in the recovery period.

The categories into which patients are grouped are as follows:

LOW RISK of thromboembolic complications (low worm burden and no parenchymal and/or pulmonary vascular lesions)

Dogs included in this group must satisfy all these conditions

- 1) **No symptoms**
- 2) **Normal thoracic radiographs**
- 3) **Low level of circulating antigens or a negative antigen test with circulating microfilariae**
- 4) **No worms visualized by echocardiography**
- 5) **No concurrent diseases**
- 6) **Permission of exercise restriction**

HIGH RISK of thromboembolic complications.

In this group should be included all the dog that don't satisfy one or more of these conditions

- 1) **Symptoms related to the disease (coughing, lipotimias, swelling of the abdomen)**
- 2) **Abnormal thoracic radiographs**
- 3) **High level of circulating antigens**
- 4) **Worms visualized by echocardiography**
- 5) **Concurrent diseases**
- 6) **No permission of exercise restriction**

Symptomatic therapy includes drugs and measures that can improve cardiopulmonary circulation and lung inflation in order to relief symptoms in dogs that cannot undergo causal therapy or to prepare them for an adulticide or surgical therapy

Restriction of exercise and in selected cases cage rest seems to be the most important measure to improve cardiopulmonary circulation and reduce pulmonary hypertension (Dillon et al 1995).

Anti-inflammatory doses of glucocorticosteroid (prednisolone 2 mg / kg s.i.d. for four or five days) given at diminishing rate can control pulmonary inflammation and thromboembolism. Diuretics (furosemide 1 mg / kg b.i.d.) are useful when right congestive heart failure is present to reduce fluid effusions. Digoxin may be administered only to control atrial fibrillation. The use of aspirin is debatable and as not secure proofs of beneficial antithrombotic effect have been reported, for this reason the empiric use of aspirin is not advised (Knight 1995).

The organical arsenical compound melarsomine dihydrochloride is actually the only used and effective heartworm adulticide

Two intramuscular injections of 2.5 mg / kg 24 hours apart are the standard regimen but dogs to reduce the risk of pulmonary thromboembolism a more gradual two step treatment is strongly advised by giving just one injection and then administering the standard pair of injections at least 50 days later (Keister et al 1992, Rawlings et al 1996). In fact, one administration of melarsomine at the dose of 2.5 mg / kg kills about 90 % of male worms and 10 % of female worms resulting therefore in 50 % reduction of the worm burden (which is safer in terms of embolism and shock). For this reason, the three-injection alternative protocol is the treatment of choice of the American Heartworm Society and several university teaching hospitals, regardless of stage of disease.

Pulmonary thromboembolism is an inevitable consequence of a successful adulticide therapy.

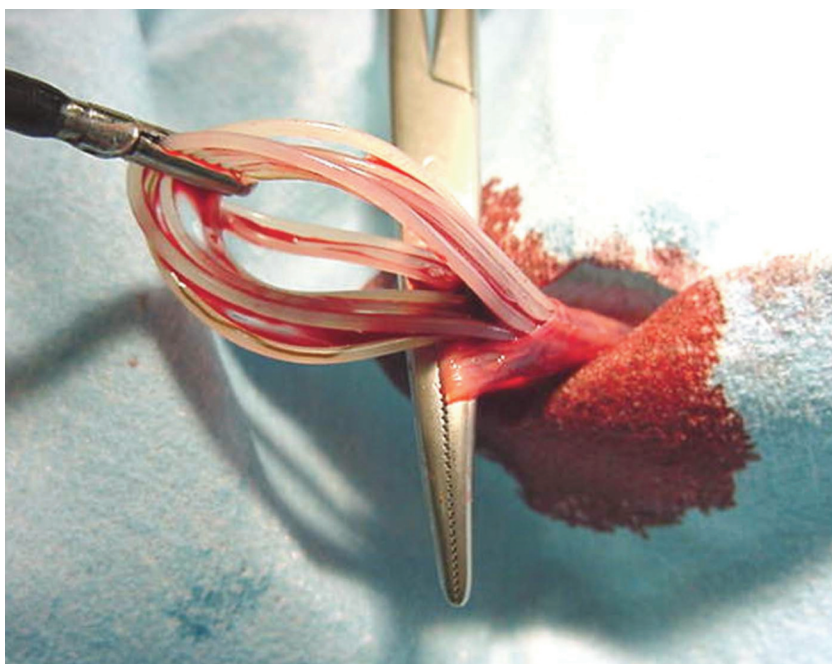
If several worms die widespread pulmonary thrombosis frequently develops.

Mild thromboembolism may be clinically unapparent but in severe cases life threaten respiratory distress can occur.

These complications can be reduced by restriction of exercise (no walks, no running around. The dog must live the indoor life or, in selected cases a cage rest) during the 30-40 days following the treatment and by administration of calcium heparin and anti-inflammatory doses of glucocorticosteroid to control clinical signs of thromboembolism (Di Sacco et al 1992, Vezzoni et al 1992, Rawlings et al 1996)

It is now known that certain macrolides have adulticidal properties (Mc Call et al 2001).

Experimental studies have shown ivermectin to have partial adulticidal properties when used continuously for 16 months at preventative doses (6-12 mcg/kg/month) and 100% adulticidal efficacy if administered continuously for over 30 months (Mc Call et al 2001).



While there may be a role for this therapeutic strategy in very few and selected cases in which patient age, financial constraints or concurrent medical problems prohibit melarsomine therapy, the current recommendations are that ivermectin not be adapted as the primary adulticidal approach, and that this kind of therapy should be used carefully. In fact, the adulticide effect of ivermectin generally requires too long before heartworms are eliminated completely. The older the worms when first exposed to ivermectin, the slower they are to die. In the meantime, the infection persists and continues to cause disease. Clinical observations suggest that heartworm-positive active dogs in prolonged ivermectin treatment may worsen if ivermectin is given monthly for 2 years (Venco et al 2004). Actual studies show that adding Doxycycline to this kind of therapy prognosis is better (probably due to the action against Wolbachia, *D. immitis* endosymbiont).

Surgical therapy is advised when several worms displacement in the right cardiac chambers produces the sudden onset of severe symptoms (caval syndrome). It can be accomplished under general anaesthesia with Flexible Alligator Forceps introduced via jugular vein

Flexible Alligator Forceps aided by fluoroscopic guidance can access not only right cardiac chambers but also pulmonary arteries.

The main pulmonary artery and lobar branches can be accessed with flexible alligator forceps, aided by fluoroscopic guidance (Ishihara et al 1990). Intra-operative mortality with this technique is very low.

Overall survival and rate of recovery by dogs at high risk of pulmonary thromboembolism is improved significantly by physically removing as many worms as possible. When the facilities are available, worm extraction is the procedure of choice for the most heavily infected and high risk dogs. Before electing this method of treatment, echocardiographic visualization of the pulmonary arteries should be performed to determine that a sufficient number of worms are in accessible locations.

Surgical removal of heartworm can avoid pulmonary thromboembolism, as compared to pharmacologic adulticides, such as melarsomine (Morini et al 1998). This procedure, however, requires specialized training and instrumentation, including fluoroscopic imaging capabilities. Nevertheless, it remains a very good and a safe alternative for the management of high risk patients and the best choice in dogs harbouring a large worm burden.

CHEMOPROPHYLAXIS

Heartworm chemoprophylaxis requires authorization by a licensed veterinarian having a valid relationship with the client and patient. To establish this relationship, heartworm prevention should be discussed with the client and if records of past treatment and testing do not exist, it is advisable to test the patient before dispensing or prescribing chemoprophylaxis.

MACROCYCLIC LACTONES

The most commonly used heartworm chemoprophylactics are the macrocyclic lactones (ivermectin, milbemycin oxime, moxidectin and selamectin). These drugs have excellent therapeutic/toxic ratios and possess anthelmintic activity against microfilariae, third- and fourth- stage larvae, and in some instances of continuous use, young adult heartworms. Some of them as milbemycin oxime have a broad spectrum even against other nematodes (milbemycin is indicated for the treatment of mixed infections by gastrointestinal nematodes such as roundworms : *Toxocara canis*, *Toxascaris leonina*, hookworms: *Ancylostoma caninum*, whipworms : *Trichuris vulpis* and if associated to Praziquantel even against tapeworms (*Dipylidium caninum*, *Taenia* spp., *Echinococcus* spp., *Mesocestoides* spp) and could be probably best used (instead of Macrocyclic lactones with narrow spectrum) in areas with low endemia or only at potential risk

The filaricidal effect of oral and topical formulations on precardiac larvae can be achieved by brief pulsing at low doses, which makes these drugs virtually 100% effective when given following label instructions and among the safest used

in veterinary medicine. All oral and topically administered macrocyclic lactone chemoprophylactic products are labeled for a monthly dosing interval.

Some Collies and other p-glycoprotein deficient dogs are unusually sensitive to a variety of commonly used veterinary drugs. The macrocyclic lactones, the only chemical class of drugs currently used for heartworm prevention, are included in this list. This sensitivity was first seen with high doses of ivermectin (in excess of 16 times the minimum effective prophylactic dose) but toxicosis has been reported with overdosing of other macrocyclic lactones as well. Often, these instances have occurred when concentrated livestock preparations of these drugs have been ingested. Dose miscalculation with extra-label use makes livestock formulations hazardous for dogs. The standard chemoprophylactic doses of medications specifically approved for dogs have been shown to be safe in all breeds.

HW DISEASE CATS

Cat is considered a susceptible but not ideal host for *Dirofilaria immitis*. Increased host resistance is reflected by the relatively low adult worm burden in natural infections (cats generally harbour 1 to 6 worms with 2 to 4 worms being the usual burden), the low number of heartworms that develop after experimental inoculation with infective larvae, the prolonged pre-patent period (8 months), the low level and short duration of microfilaremia, and the short life span of adult worms (2-3 years). In cats changes in pulmonary arteries and lungs after infection seem to be similar but right cardiac chambers well bear pulmonary hypertension and right cardiac heart failure is an unusual finding.

In cats symptomatology is quite different than in the canine counterpart.

Most cats seem to well bear the infection for long time. These cats may have a spontaneous self-cure due to the natural

death of parasites without any kind of symptomatology or suddenly may show dramatic acute symptoms.

The most common clinical observed signs in cats are cough and dyspnoea sometimes associated to vomiting not related to food, or rarely vomiting alone

Sudden death in apparently healthy cats is furthermore a typical evenience.

Chronic symptomatologies including coughing, vomiting, diarrhoea, weight loss can be less frequently observed.

On the contrary than in dogs, symptomatology related to right ventricular heart failure is not considered consistent with heartworm infection in cats.

The onset of symptoms in most cases seems to be related to the natural death of parasites or to the first arriving of L5 heartworms in the pulmonary arteries.

DIAGNOSIS

BLOOD TEST FOR MICROFILARIAE

As microfilaremia in cats is unlikely, sensitivity of test for detection of circulating microfilariae is very low despite specificity is considered 100 % as in dogs in cats too.

BLOOD TEST FOR ADULT ANTIGENS

Test detecting adult heartworm antigens can provide a definitive proof of infections in cats because of the very high specificity. Unfortunately, as in cats usually worm burden is very light, infections caused only by male heartworms are not infrequent and often symptomatology may be due to immature worms these tests in a large average yield false negative result. A negative test cannot therefore be considered sufficient to rule out the infection (Atkins et al 1995).

In cats serum samples which test false negative on commercial assays, because of antigen may be trapped in immune complexes, preventing detection (antigen masking) are more common than in dogs. Heat treatment of samples

prior to testing, as these complexes are disrupted increases their sensitivity.

BLOOD TEST FOR ANTIBODIES TO ADULT HEARTWORM

Due to the low sensitivity of tests for circulating microfilariae and adult antigens in cats, test for detection of antibodies to adult heartworm can be useful used.

Antibody tests are currently available for routine screening of feline heartworm infection, either as 'inclinic tests' or laboratory tests. Antibody testing provides information about previous exposure but not necessarily about current infection. Consequently, antibody tests are more useful to rule out rather than confirm the infection.

This kind of test has high sensitivity but not complete specificity because of cross reactivity with other parasites or antibodies to abortive infections, with a reported sensitivity between 62-72 percent and specificity between 81-98 percent

Consequently, antibody tests should be interpreted carefully, taking other relevant clinical information into consideration.

THORACIC RADIOGRAPHS

Thoracic radiographs are an important tool for the diagnosis of feline heartworm disease. Despite thoracic abnormalities in few cases are absent or transient, typical findings as enlarged peripheral branches of the pulmonary arteries accompanied by varying degrees of pulmonary parenchymal disease are strongly consistent with heartworm infection

Enlargement of the main pulmonary artery cannot be observed because this tract of artery is obscured by cardiac silhouette. Right sided cardiomegaly is not considered a typical finding in cat

NON SELECTIVE ANGIOCARDIOGRAPHY

Non selective angiocardiology is useful in visualization the gross morphology of the pulmonary arteries.

Seldom the heartworms can be seen as negative filling defects within opacified arteries.

ELECTROCARDIOGRAPHY

Heartworm infection does not involve right cardiac chambers. Consequently, electrocardiography cannot provide useful information in infected cats.

ECHOCARDIOGRAPHY

Cardiac ultrasound allows the direct visualization of the parasites in right atrium and ventricle, main pulmonary artery and proximal tract of both its peripheral branches.

Specificity is virtually 100 % and sensitivity in cats seems to be very high as only a short portion of caudal pulmonary arteries compared with the length of the parasite cannot be thoroughly interrogate because off the acoustic impedence of the air inflated lungs. Based on these considerations cardiac ultrasonography should be always performed when heartworm infection is suspected.

TRANSTRACHEAL LAVAGE

The presence of eosinophils in a tracheal wash, with or without eosinophilia, may be noted 4 to / months after infection but this finding is not specific and infection with other pulmonary parasites (*Paragonimus kellicotti*, *Aelurostrongylus abstrusus*) and allergic pneumonitis or asthma should be ruled out.

THERAPY

Diminishing doses of prednisone are advised in cats in order to relief respiratory distress. The dosage is 2 mg/ kg dally initially, then declining to 0.5 mg / kg every other day for two weeks, and then discontinuing treatment after an additional two weeks. Injectable formulation (even long acting) seems to be more effective than oral ones.

If crisis is due to embolization of dead worms high doses of prednisone (1-2 mg/kg 3 times a day) are recommended

Thiacetarsamide is the only arsenical compound of which use was described in cats in the field

The same dosage and regimen used in treating dogs, 2.2 mg / kg twice daily for two days, was used for cats.

The use of this drug in cat is debatable. Early reports showed some toxicity in heartworm naive cats, but later reports showed that thiacetarsamide delivered to normal cats produced no respiratory distress or altered the body temperature However a large average heartworm infected cats develop acute respiratory distress or sudden death in the post-treatment period. This effect seems to be due to embolization associated with worm death (Dillon et al 1992)

Thee use of melarsomine in cats is not advised because the incomplete efficacy in killing worm at the same regimen used in dogs (2,5 mg/kg) and the high toxicity in this species (3,5 mg/kg may result in dead of the treated cat)

Due to these reasons macrofilaricide treatment is not advised in cats unless selected situations

In cases of caval syndrome or when a heavy worm burden is visualized by echocardiography in right cardiac chambers surgery may be attempted. Worm can be extracted via jugular vein using thin alligator forceps, horse hair brush or basket catheters.

The incidental rupture of worms during the procedure may result in the dead of the cat (till 30% of cases). Heartworm surgical removal in cats for this reason is not considered in cats as safe as in dogs.

Because of the small size of the feline heart pulmonary arteries cannot be accessed.

SUBCUTANEOUS DIROFILARIOSIS

Dirofilaria repens, is the causative agent of canine and feline subcutaneous dirofilariosis, a mosquito borne disease that has become increasingly recognized in several countries in southern and central Europe, Africa and Asia. *D. repens* life cycle, like that of *Dirofilaria immitis*, consists of 5 larval stages which develop both in a vertebrate host and an arthropod (mosquito), intermediate host and vector. Adult female worms produce thousands of embryos (microfilariae) that are ingested by a blood-feeding insect. Microfilariae have a unique circadian periodicity in the peripheral circulation over a 24-hour period. The arthropod vectors also have a circadian rhythm in which they obtain blood meals. The highest concentration of microfilariae usually occurs when the local vector is most actively feeding. Microfilariae then undergo 2 developmental moults in the insect. During feeding, the infected mosquito deposits third-stage larvae throughout a drop of haemolymph in the proximity of bite wound from where larvae actively migrate to subcutis. Larvae develop to the adult stage through moults in the vertebrate hosts. Prepatency lasts 6 1/2 to 9 months. The adults reside in the subcutaneous tissues of dogs and cats and may cause mild clinical signs such as pruritus, dermal swelling, subcutaneous nodules or no symptoms at all.

Despite the usual hosts of *D. repens* are domestic and wild carnivores, human beings may act as accidental and dead-end hosts and a big concern about zoonotic human cases is arising. Human infection manifests with either subcutaneous nodules, ocular or lung parenchymal nodules mostly asymptomatic. The significance of infection in humans is that pulmonary and some subcutaneous lesions are commonly labelled as malignant tumours requiring invasive investigation and surgery before a correct diagnosis is made. The pathology of the condition is associated with aberrant localization of immature worms that do not reach adulthood; therefore, microfilariae are almost always absent (Pampiglione et al., 1995).

DIAGNOSIS

BLOOD TEST FOR MICROFILARIAE

Detection of circulating microfilariae using the method developed by Knott is the best way for doing an in vivo diagnosis but collection of histopathological cutaneous specimens. Larvae species determination is made on the basis of morphological or histochemical method or by using PCR.

BLOOD TEST FOR ADULT ANTIGENS

Tests detecting adult heartworm (*D. immitis*) do not detect *D. repens* antigens and no cross reactivity is described.

THERAPY

No adulticide treatment for *D. repens* is registered and an off-label use of melarsomine has only recently been described on the basis of a case report where combined therapy with the arsenic adulticide melarsomine and the avermectin microfilaricidal doramectin was effective in clearing infection with *D. repens* a dog, although the death of the patients does not allow conclusive evidences. Symptomatic therapy of canine dirofilariosis due to *D. repens* indicated for dogs suffering from clinical signs of this disease, such as dermal swelling, sub-cutaneous nodules and pruritus. Steroids and/or antibiotics administration and nodules surgical removal may be suggested in these cases for relieving symptoms. Some macrocyclic lactones (ivermectin, moxidectin, selamectin) are claimed to be effective for the prevention of *D. repens* infection in dogs and labelled for this use in some country (Italy) on the basis of field study. While there is no doubt that they are able to prevent microfilaremia in dogs (and this is important for zoonotic implications), as most of the performed studies were not based on necropsy confirmation some concerns about the ability of completely preventing infection in dogs still remain

REFERENCES

- Atwell RB, Buoro BJ 1988 Caval syndrome. In: Boreman PFL, Atwell RB Eds. *Dirofilariasis* Boca Raton, CRC Press Inc. 191 – 203
- Badertscher RR, Losonsky JM, Paul AJ, Kneller SK 1988 Two dimensional echocardiography for diagnosis of dirofilariasis in nine dogs *JAVMA* 193 ; 7 843-846
- Calvert CA, Rawlings CA. 1988 Canine Heartworm Disease In: *Canine and Feline Cardiology* Fox Pr Ed. Churchill Livingstone Inc. 519-549
- Dillon R., Warner AE, Molina RM. 1995 Pulmonary parenchymal changes in dogs and cats after experimental transplantation of dead *Dirofilaria immitis*. In: Soll MD and Knight DH eds. *Proceedings of the heartworm Symposium '95 Auburn Alabama Batavia Illinois American Heartworm Society* 97-101
- Dillon R, Brawner WR, Hanrahan L 1995 Influence of Number of Parasites and Exercise on the Severity of Heartworm Disease in Dogs In : Soll MD and Knight DH eds *Proceedings of the '95 Heartworm Symposium Batavia Illinois American Heartworm Society* 113
- Di Sacco B, Vezzoni A 1992 Clinical classification of heartworm disease for the purpose of adding objectivity to the assessment of therapeutic efficacy of adulticidal drugs in the field. In: Soll M.D. Ed *Proceedings of the Heartworm Symposium '92 Batavia Illinois: American Heartworm Society* 209 - 214.
- Ishihara K, Kitagawa H, Sasaki Y 1990 Efficacy of Heartworm removal in Dogs with *Dirofilarial Hemoglobinuria* using Flexible Alligator Forceps. *Jpn. J. Vet.Sci.* 53(3): 591-599
- Keister D.M, Dzimianski M.T, MC Tier TL et al. 1992 Dose selection and confirmation of RM 340, a new filaricide for the treatment of dogs with immature and mature *Dirofilaria immitis*. In: Soll MD, Ed *Proceedings of the Heartworm Symposium '92 Batavia Illinois: American Heartworm society*
- Kitagawa H, Sasaki Y, Ishiara K 1987 Canine *dirofilaria hemoglobinuria*: changes in right heart hemodinamics and heartworm migration from pulmonary artery toward right atrium following beta - blocker administration. *Jpn. J.Vet.Sci.* 49; 1081 - 1086
- Knight DH 1995 Guidelines for diagnosis and management of heartworm (*Dirofilaria immitis*) infection. In: Bonagura JD ed. *Kirk's Current Veterinary Therapy XII Small Animal Practice*. WB Saunders Co.
- Mc Call JW 1992 a parallel between experimentally induced canine and feline heartworm disease *Proceedings of XVII WSAVA world congress*. Delfino Ed. Rome, Italy 24th-27th September 1992 255-261
- McCall JW, Guerrero J, Roberts RE et al. Further evidence of clinical prophylactic (reach-back) and adulticidal activity of monthly administration of ivermectin and pyrantel pamoate in dogs experimentally infected with heartworms. In Seward, L., ed. *Proc Amer Heartworm Sym '01*. Batavia, IL: American Heartworm Society, 2001; 189-200.
- Moise NS 1988 Echocardiography In: *Canine and Feline Cardiology* PR Fox Ed. New York, Churchill Livingstone Inc. pp 113-156
- Morini S, Venco L, Fagioli P, Genchi C. Surgical removal of heartworms versus melarsomine treatment of naturally-infected dogs with risk of thromboembolism. In Seward, L., ed. *Proc Amer Heartworm Sym '98*. Batavia, IL: American Heartworm Society, 1998; pp235-240.
- Rawlings CA 1986 Heartworm disease in dogs and cats WB Saunders Co. Philadelphia) Pampiglione S, Canestri Trotti G, Rivasi E, 1995. Human dirofilariasis due to *Dirofilaria (Nochtiella) repens*: a review of world literature. *Parassitologia* 37: 149-193.
- Rawlings CA, Mc Call JW 1996 Melarsomine: A New Heartworm Adulticide *Compend Cont Ed* 18 (4) 373- 379
- Venco LA 1993 Approccio diagnostico alla sindrome della vena cava *Veterinaria SCIVAC Ed.(Cremona)* 7 11 - 18 (in Italian).
- Venco L, Genchi C, Vigevani Colson P, Kramer L.2003 Relative utility of Echocardiography, Radiography, Serologic testing and Microfilariae counts to Predict Adult Worm Burden in Dogs Naturally Infected with Heartworms. In: Seward LE, Knight DH Eds *Recent Advances in Heartworm Disease. Symposium '01*. American Heartworm Society. Batavia (IL) 111-124
- Venco L, Mc Call JW, Guerrero J, Genchi C. 2004 Efficacy of long-term monthly administration of ivermectin on the progress of naturally acquired heartworm infections in dogs. *Vet Parasitol.* Oct 5; 124(3-4):259-68
- Vezzoni A, Genchi C, Raynaud JP 1992 Adulticide efficacy of RM 340 in dogs with mild and severe natural infections. In: Soll M.D., ed. *Proceedings of the Heartworm Symposium '92 Batavia Illinois: American Heartworm Society*, 231 - 240.